

A CASE REPORT: CEREBRAL SINUS VENOUS THROMBOSIS PRESENTING WITH NYSTAGMUS HORIZONTAL BIDIRECTIONAL

Dharma K. IB Budha¹, Tini, Kumara², Wijayanti, IA Sri², Susilawathi, Ni Made²,
Putri M. Ni Putu Ayu², Agung Pramaswari, AA. Ayu²

¹Departement of Neurology, Udayana University Hospital, Badung, Bali, Indonesia

DOI: <https://doi.org/10.5281/zenodo.10435660>

Published Date: 27-December-2023

Abstract: Background: Cerebral sinus venous thrombosis (CSVT) is a rare case of stroke. The prevalence of CSVT in women is three times higher than in men, with the most frequent complaint being headache with a migraine-like pattern accompanied by accompanying complaints resembling stroke. Management for CSVT in the acute phase is anti-coagulants, either Unfractionated Heparin (UFH) with adjusted doses or Low Molecular Weight Heparin (LMWH), with mortality depending on the location of thrombosis and neurological status.

Case: In the case of a 25 years old man with the main complaint of headache that felt throbbing throughout the area of the head since 1 day ago which got worse and worsened with activity or coughing. Patients also complain of double vision which improves when one eye is closed. Neurological examination revealed left ocular papilledema, bidirectional horizontal nystagmus, binocular diplopia. Computed Tomography Venography (CTV) revealed an empty delta sign, thrombosis in the sigmoid sinus Dextra, distal internal jugular vein Dextra, transverse sinus Dextra, superior sagittal sinus. The patient received UFH for 5 days and the patient's condition improved. Next, the patient was planned for DSA.

Keywords: Cerebral Sinus Venous Thrombosis, CSVT, migrain-like, D-Dimer.

I. INTRODUCTION

Cerebral sinus venous thrombosis (CSVT) is a rare case of stroke. The incidence rate of CSVT cases is 0.5% - 1% of all stroke cases, and the annual incidence is 0.22 - 1.32 cases per 100.000 population. CSVT can occur in young individuals, as well as children, with the prevalence rate in women being three times higher than in men.^{[1],[2]} However, at ages over 60 years, the prevalence is the same for women and men. The risk factors for CSVT can vary, but only some are reversible.^{[1],[2],[3]}

Signs and symptoms of patients with CSVT vary widely. The most common symptom found is headache which has a migraine-like pattern due to increased intracranial pressure, with accompanying complaints resembling a stroke. The development of signs and symptoms in CSVT is relatively slow. This causes quite a few misdiagnoses or delays in diagnosing CSVT.^{[1],[3]} In diagnosing CSVT, cerebral imaging is very important to detect thrombus although laboratory examinations are also important in determining other possible causes. CSVT cannot be diagnosed without imaging. There are several options that can be used, one of which is non-invasive cerebral imaging, Computed Tomography Venography (CTV), and Magnetic Resonance Venography (MRV).^{[1],[2],[3],[4],[5]} The most common venous locations where thrombus occurs are the transverse sinus (44 – 73%), superior sagittal sinus (39 – 62%), sigmoid sinus (40 – 47%), deep venous system (10.9%) and cortical veins (3 .7 – 17.1%).^[3]

Management of CSVT cases greatly influences the patient's development. Anticoagulation is a therapeutic option in the acute phase, namely Unfractionated Heparin (UFH) with an adjusted dose or Low Molecular Weight Heparin (LMWH) and followed by adequate monitoring of the patient's hematology. Management of CSVT also relies heavily on additional therapy and preventing other complications.^{[1],[4]}

II. CASE REPORT

25-year-old male patient, Indonesian, Balinese, Hindu, tattoo artist, right-handed, referral from Surya Husada Hospital Denpasar came to the Emergency Room (IGD) on August 18 2023 with complaints of headaches since 1 day ago felt all over the head. The pain is said to feel like throbbing from the front of the head to the back of the head and the pain is felt to be more severe than 1 day ago, but the patient is still able to endure the pain. Complaints of headaches feel worse when the patient is straining or coughing. The patient also complained of nausea and vomiting along with headaches. Vomiting begins with a feeling of nausea. Projectile vomiting is denied.

The patient complained of feeling double vision when looking at the surrounding environment with both eyes open when complaints of headaches appeared. Denied complaints of dizziness. Complaints improve when the patient closes one eye. The patient said that before the headache complaint appeared, the patient complained of feeling feverish since 1 day before the headache complaint appeared (17 August 2023). The patient had time to measure his body temperature with a thermometer and found the temperature to be 39^oC. The patient also felt sore throat and runny nose since 1 day before the headache appeared. Other complaints such as slurred speech, weakness in half of the body, pursed lips are denied. Denied history of weight loss.

Based on the patient's statement, the patient had never had complaints such as headaches accompanied by nausea, vomiting, and seizures like this before. The patient has a previous history of frequent heartburn or stomach ulcers. The patient has a history of hypertension since the age of 8 years and does not take medication. The patient has been an active smoker for 8 years with a frequency of 12 cigarettes per day, and the patient has a history of alcohol consumption.

Based on the physical examination when he first came to the emergency room, the patient's consciousness was compos mentis with GCS E4V5M6, blood pressure 140/90 mmHg, heart rate 102 beats per minute, respiratory rate 28 times per minute with SpO₂ 99% room air, and axillary temperature 36^oC. Neurological examination revealed left ocular papilledema, bidirectional horizontal nystagmus, binocular diplopia. No lateralization, pathological reflexes, or cranial nerve paresis were found. Laboratory examinations that have been carried out are complete blood, blood chemistry such as BUN, SC, Sodium, Potassium, liver function, D-Dimer, with supporting examinations in the form of ECG, Anteroposterior Chest X-Ray, Echocardiography, and CT-Scan of the head without contrast.

TABLE 1: Complete Blood Count

Test	Result	Unit
MCHC	33.7	g/dL
Lym%	4.7	%
Lym#	0.26	10 ³ /uL
Bas#	0.01	10 ³ /uL
Bas%	0.2	%
Neu%	90.4	%
Eos%	0.0	%
Mon%	4.7	%
Neu#	5.04	10 ³ /uL
Eos#	0.00	10 ³ /uL
Mon#	0.26	10 ³ /uL
PDW	8.9	fL
Haematocrit	50.2	%
MCH	26.9	Pg
RDW-CV	12.8	%

MCV	79.8	fL
RDW-SD	36.8	fL
MPV	8.7	fL
PCT	0.16	%
White Blood Cell	5.57	10 ³ /uL
Platelet	186	10 ³ /uL
Red Blood Cell	6.29	10 ⁶ /uL
Haemoglobin	16.9	g/dL

TABLE 2 Others

Test	Result	Unit
<i>Serum Glutamic Oxaloacetic Transaminase</i>	60	U/L
<i>Serum Glutamic Pyruvic Transaminase</i>	74	U/L
Serum Creatinine	1.28	mg/dL
Ureum	14.5	mg/dL
Sodium	138	mmol/L
Potassium	3.5	mmol/L
Calcium	9.1	mg/dL
D-Dimer	808	ng/ml FEU

Vital signs show that the patient has grade I hypertension, with an ECG sinus rhythm of 89 beats per minute, normal axis. Laboratory examination showed an increase in D-Dimer. The chest X-ray showed that the lung and heart conditions were within normal limits with a Cardio Thorax Ratio (CTR) of 45%. Echocardiography examination was within normal limits with an Ejection Fraction (EF) of 76.3%. On an axial CT scan of the head without contrast, diffuse cerebral edema was found (**Figure 1**).

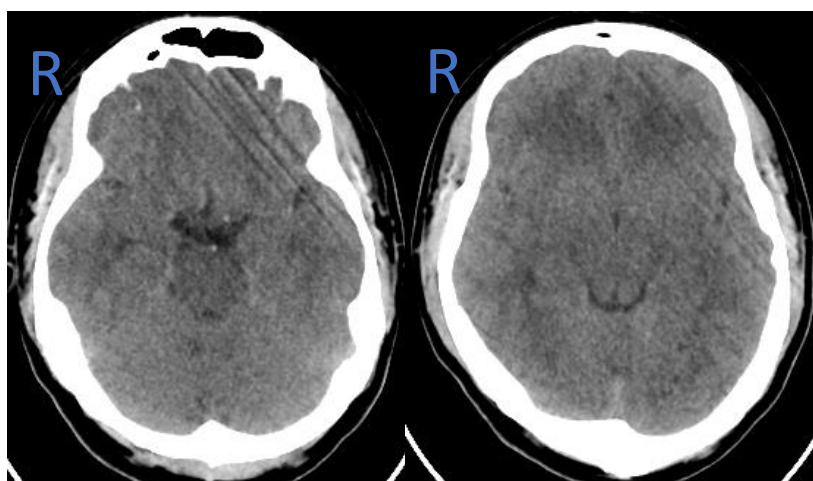


Fig 1. Head CT-Scan without Contrast Axial Section

The patient's diagnosis was Cefalgia Red Flag ec susp Intracranial Hypertension dd CSVT, HT stage I. The patient's treatment was given IVFD NaCl 0.9%, head up 300, Corticosteroids, PPI, Laxatives, painkillers in the form of Paracetamol flash and ibuprofen. The patient was suspected of having CSVT which was further confirmed by CT angiography (Venography). On an axial CT venography examination, a filling defect or known as the "empty delta sign" was found in the transverse sinus. On sagittal section, a filling defect was found in the superior sagittal sinus (**Figure 2**). 3D Venography showed thrombosis in the Dextra sigmoid sinus, distal internal jugular vein Dextra, transverse sinus Dextra, superior sagittal sinus (**Figure 3**). The patient was then planned for serial hematology examinations and given unfractionated heparin at a dose of 5000 IU with a follow-up dose of 500 - 1000 IU units with a target APTT increasing 2 - 2.5 times the basic APTT in the High Care Unit (HCU).

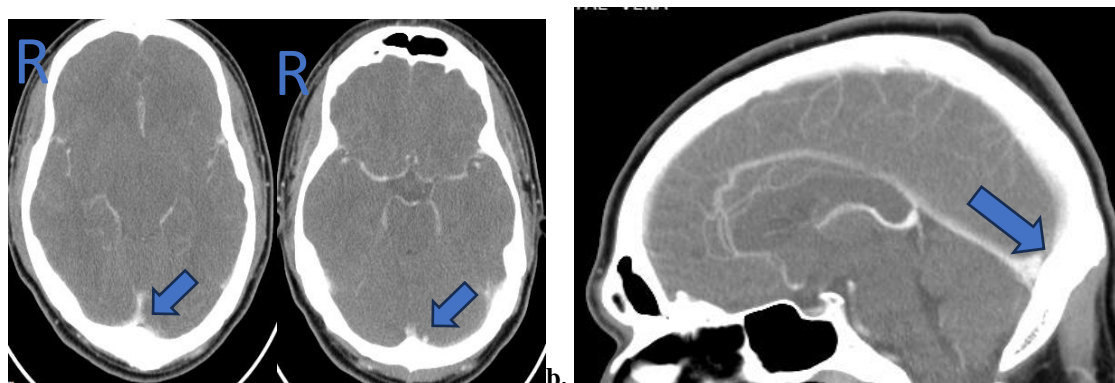


Fig 2. CT Venografi. a. Axial Section (Filling defect sinus transversus) b. Sagittal Section (Filling defect sinus Sagitalis superior)

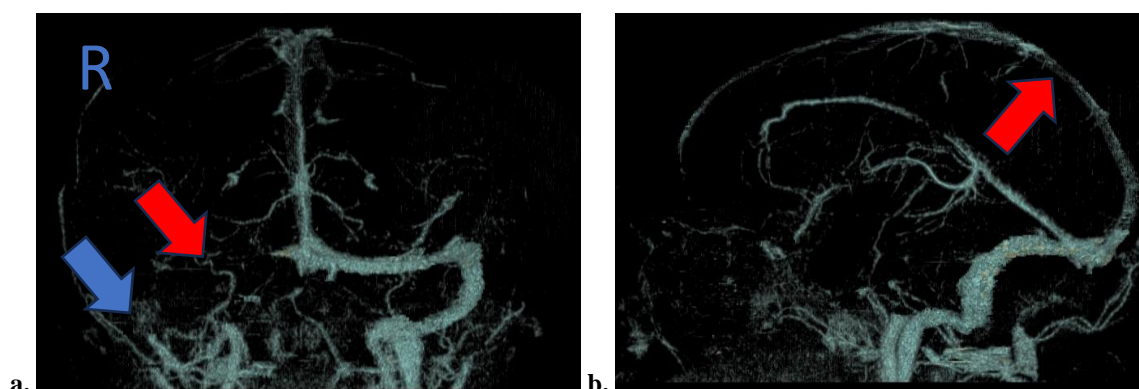


Fig 3. Venografi 3D a. Thrombosis in Sigmoid Sinus D, distal vein internal jugular D, and Transversus Sinus D b. Thrombosis superior sagittal sinus

After administering the first unfractionated heparin with a loading dose, it was found that the APTT increased by 4 times from the previous baseline value, and this value experienced a significant decrease after continuing with the maintenance dose which was adjusted to the laboratory findings until the desired APTT target was achieved. On the 8th day of treatment (26/8), heparinization of the patient was stopped and therapy was started with oral anticoagulant, namely rivaroxaban 2 x 20 mg IO, ACE inhibitor, and Calcium Channel Blocker. During treatment, the patient's headache complaints improved and the patient's double vision was denied with a blood pressure of 134/82 mmHg. On neurological physical examination, nystagmus was no longer found. On the 9th day of treatment, the patient was planned to go home and be checked again 3 days later with DSA planning.

III. DISCUSSION

Cerebral Sinus Venous Thrombosis (CSVT) is a rare stroke with a small incidence in all stroke cases. CSVT usually attacks young individuals and children, with a prevalence of women three times more often than men. However, at the age of more than 60 years, the prevalence of incidence is the same between men and women. There are several risk factors for CSVT itself, namely prothrombic conditions, infection, mechanical trauma, vasculitis, intracranial structural defects, malignancy, hematology, systemic diseases or disorders, and medications.^{[1],[2],[3],[5]} In this patient the only risk factors are found is in the form of young age, namely 25 years.

CSVT can be classified based on onset, namely acute (<48 hours), subacute (>48 hours – 30 days), and chronic (>30 days). Meanwhile, based on the cause, it can be divided into 2 types, namely provoked (if there are risk factors) and unprovoked (the cause cannot be identified).^{[1],[2],[6]} Patients with CSVT have clinical manifestations in the form of stroke-like syndrome, with the most frequent main complaint being headache (in 90% of cases). Headaches can be diffuse, or have a migraine-like pattern. Complaints can be accompanied by double vision, craniofacial pain (pain in the ear, or mastoid with or without fluid) which can occur due to mastoiditis, seizures, focal neurological deficits, papilledema, and decreased consciousness.^{[1],[2],[6],[7]} All of these accompanying complaints can occur as a result of increased ICP, or focal lesions in the deep veins, and complications occur in the form of focal infarction or haemorrhage.^{[6],[7]} In this patient, based on the onset,

it is in the acute phase, namely <48 hours and is unprovoked or the cause cannot be identified. The patient's clinical manifestation was good awareness, namely *compos mentis*, with the main complaint being headache throughout the entire area of the head that felt like it was throbbing accompanied by nausea and vomiting, and the complaint felt worse when the patient pushed or was active. Another complaint is blurred vision which is felt when the patient looks with both eyes open, which improves when one eye is closed.

Physical examination revealed left ocular papilledema, bidirectional horizontal nystagmus, and no cranial nerve paresis. This occurs due to increased ICP due to decreased venous drainage caused by thrombus in the vein (the most common cause of increased ICP is thrombosis in the superior sagittal sinus). Apart from that, this can be caused by decreased drainage in the cavernous sinus which results in increased pressure in the cavernous sinus.^{[6],[7],[8]} This can occur due to disruption of blood flow from the cavernous sinus to the following veins, namely the transverse sinus, internal jugular vein, or other veins. facials. In the cavernous sinus, several cranial nerves cross, namely the oculomotor nerve (N. III), trochlear nerve (N. IV), abducens nerve (N. VI) and the first and second branches of the facial nerve (N. V₁, N. V₂). Pressure on the cranial nerves can cause diplopia, paresthesia (in the eyes, nose, and forehead), impaired eye movement, and nystagmus.^{[7],[8],[9]}

On laboratory examination, an increase in D-Dimer levels >500 ng/ml FEU was found. This is in accordance with the AHA/ASA guidelines regarding cerebral venous thrombosis, where the more acute the CSVT event, the higher the D-Dimer levels.^{[1],[2],[4],[10]} The patient underwent a head CT-Scan without contrast and found cerebral edema. This is caused by thrombus in the sinuses/veins causing accumulation of fluid in the blood vessels resulting in vasogenic and cytotoxic edema.^{[1],[2],[3],[5],[7],[11]} If this is not handled properly it will cause damage to the blood-brain barrier and risk of hemorrhagic infarction. Head CT scans without contrast very rarely show signs typical of CSVT due to anatomical variability so that CT scans without contrast are insensitive. However, the results of a CT-Scan without contrast which does not show signs of CSVT do not simply eliminate suspicion of CSVT so that further examination is needed in the form of CT-scan Venography or MRV.^{[1],[2],[4],[7]} In CT-scans with contrast or CT- Scan venography (CTV) can show signs that are typical for CSVT, namely the Empty Delta Sign. This is caused by slow or almost no flow in the sinuses surrounded by contrast.^{[1],[2],[5],[6]}

On the axial CT Venography examination, the patient found a filling defect or known as the "empty delta sign" in the transverse sinus. On sagittal section, a filling defect was found in the superior sagittal sinus. On 3D Venography, it shows thrombosis in the Dextra sigmoid sinus, distal Dextra internal jugular vein, Dextra transverse sinus, superior sagittal sinus. This is in accordance with the patient's clinical condition where the location of the venous thrombus that most often causes increased ICP is the superior sagittal sinus.^{[2],[3],[4],[7],[8]}

In the acute phase management, patients are given anticoagulants, namely unfractionated heparin with a loading dose of 5000 IU followed by a dose of 500 - 1000 IU with a target APTT increasing 2 - 2.5 times the patient's basic APTT (32.9 seconds), analgesics in the form of paracetamol and ibuprofen, and IV corticosteroids. Giving anticoagulants in the acute phase aims to prevent thrombus growth and facilitate recanalization of the affected sinus. Although this has caused some controversy, several research results show that the reduction in mortality and improvement in the prognosis of CSVT patients with anticoagulants and without anticoagulants show significant differences. Giving anticoagulants to CVST patients is very safe and effective regardless of the presence of ICH before treatment.^{[1],[2],[3],[4],[12]} There is no difference in results between UFH with adjusted doses and LMWH in CSVT patients.^{[2],[3],[12]} Other treatments are Corticosteroids are only given if there are comorbidities, such as to reduce vasogenic edema. Treatment for seizures is only given if there are periods of seizures without or with parenchymal lesions.^{[1],[2]}

Surgery can be considered if there is a deterioration in the neurological condition due to a heavy intracranial mass so that decompressive hemicraniectomy can be considered. Long-term management of patients with CSVT is to reduce the risk of recurrence with vitamin K antagonists or anticoagulants. For provoked CSVT, the duration of drug administration is 3 – 6 months with a target INR of 2 – 3, Unprovoked CSVT 6 – 12 months with a target INR of 2 – 3, if recurrent CVT, VKA or anticoagulant administration can be given for life with a target INR of 2 – 3. Administration DOACs are more effective than warfarin but are not first line therapy. If during outpatient treatment the patient complains of headaches but the MRI results are within normal limits, Lumbar puncture can be performed to exclude increased ICP. Visual loss can be carried out by further visual field examination and collaboration with an ophthalmologist.^{[1],[2],[3],[4],[6],[7],[12]}

The prognosis for CSVT varies greatly. Worsening of neurological status occurs in 23% of patients, even several days after diagnosis. Worsening neurological status is decreased consciousness, seizures, worsening of focal neurological deficits, increased intensity of headaches or loss of vision. The mortality rate for CSVT patients in the acute phase is 3 – 15%. This

occurs due to several risk factors based on the International Study on Cerebral Venous and Dural Sinuses Thrombosis (ISCVT), namely decreased consciousness, disturbed mental status, and thrombosis in the deep venous system, intracranial hemorrhage, and posterior fossa lesions. The main cause of acute phase death in CSVT is transtentorial herniation, and the second is extensive bleeding lesions, diffuse brain edema. The long-term prognosis of CSVT patients has a mortality rate of 8.3%. This is caused by infection, deep venous system thrombosis, intracranial hemorrhage on CT/MRI upon arrival, GCS score <9, disturbed mental status, age >37 years, and male gender. Cerebral herniation is the most common cause of death in young patients. The incidence of recanalization in CSVT at 3 months and 1 year of follow-up was 84% and 85% with the highest incidence of recanalization occurring in deep cerebral vein and cavernous sinus thrombosis.^{[1],[2],[3],[7]}

IV. CONCLUSION

Cerebral Sinus Venous Thrombosis (CSVT) is a rare stroke. A person with CSVT will have a variety of complaints, but the most frequent complaint is headache with a migraine-like pattern which can be accompanied by complaints similar to a stroke with varying onset. CSVT can be provoked or unprovoked based on existing risk factors. On supporting examination, CT-scan without contrast may not show a typical picture but most often shows cerebral edema, or bilateral or parasagittal lesions that cross the arterial territory. This does not reduce the suspicion of CSVT so that other supporting examinations such as CTV/MRV are needed and can be clarified with DSA. In the management of acute phase CSVT it is very important to initiate anticoagulation either UFH with adjusted doses or LMWH with close monitoring of the patient's hematology. And continued with oral anticoagulants. CSVT has a good prognosis and low rates of recurrence, disability, and mortality.

REFERENCES

- [1] Saposnik., et al. 2011. Diagnosis and Management of Cerebral Venous Thrombosis. *AHA Journals*.;42:1158-1192.
- [2] Idiculla, Pretty Sara., Et al. 2020. Cerebral Venous Thrombosis: A Comprehensive Review. *European Neurology*; 83:369 – 379.
- [3] Junior, Anisio Adalio de A.M., Confroto, Adriana Bastos. 2022. Cerebral venous thrombosis. *Arq Neuropsiquiatr*;80(5 Suppl. 1):53-59.
- [4] Capecchi, M., Abbattista, M., Martinelli, I. 2018. Cerebral Venous sinus Thrombosis. *Journal of Thrombosis and Haemostasis*; 16:1918 – 31.
- [5] Sadik, J.-C.; Jianu, D.C.; Sadik, R.; Purcell, Y.; Novaes, N.; Saragoussi, E.; Obadia, M.; Lecler, A.; Savatovsky, J. 2022. Imaging of Cerebral Venous Thrombosis. *Life*. MDPI;12: 1215.
- [6] Behrouzi, Roya.; Punter, Martin. 2018. Diagnosis and management of cerebral venous thrombosis. *Royal College of Physicians*; 18: 75 – 9.
- [7] Plewa, MC.; Tadi, p.; Gupta, M. 2023. Cavernous Sinus Thrombosis. StatPearls Publishing.
- [8] Moini, Jahangir.; Piran, Pirouz. 2020. Functional and Clinical Neuroanatomy. Academic Press. P 131 – 176.
- [9] Bousser, Marie-Germaine.; Barnett, Henry J.M. 2004. *Stroke* 4th Edition. Churchill Livingstone. p301 – 325.
- [10] Dakay, Katarine., et al. 2021. Cerebral Venous Sinus Thrombosis in COVID-19 Infection: A Case Series and Review of The Literature. *Elsevier*; 30 (1): 1 – 7.
- [11] Murphy, Stephen JX.; Werring, David J. 2020. *Stroke: causes and clinical features*. Elsevier; 48:9.
- [12] Coutinho, J.; de Bruijn, SFTM.; Deveber, G.; Stam, J. 2011. Anticoagulation for cerebral venous sinus thrombosis (Review). *John Willey and Sons*; 8: 1 – 12.